THE KANSAS UNIVERSITY SCIENCE BULLETIN.

VOL. X., No. 12—JANUARY, 1917.

(Whole Series, Vol. XX, No. 12.)

CONTENTS:

THE FUNCTION OF THE SUPRAGLENOID CANAL, ... *Herman Douthitt.*

PUBLISHED BY THE UNIVERSITY,

LAWRENCE, KAN.

Entered at the post office in Lawrence as second-class matter.

7-111

KANSAS STATE PRINTING PLANT.
W. R. SMITH, State Printer.
TOPEKA, 1917.

THE KANSAS UNIVERSITY SCIENCE BULLETIN.

VOL. X, No. 12.] JANUARY, 1917. [WHOLE SERIES VOL. XX, No. 12.

The Function of the Supraglenoid Canal.

BY HERMAN DOUTHITT.

SEVERAL months ago the writer was discussing with Professor Williston the presence in *Diplocaulus* of the supraglenoid foramen, a structure which has been recognized in nearly all Permian reptiles, and in the Temnospondyli. Professor Williston stated that he had been surprised to note that the same foramen occurs in the lizards, where its presence had apparently been completely overlooked. He suggested that the writer study its function in the lizard, with the view likewise of determining its function in the early Tetrapoda.

With this end in view, the writer has made a careful study of the collared lizard, *Crotaphytus collaris*. Part of the material used was secured from the Dyche Museum of Natural History. I wish here to acknowledge the courtesy of Mr. C. D. Bunker in placing this material at my disposal. Fresh material has likewise been collected, and the arteries injected.

The supraglenoid canal, or foramen, occurs in two distinct forms. In lizards and Temnospondyli, in most Cotylosauria at least, and in some Thermorpha, as *Edaphosaurus* and *Ophiacodon*, its external opening is on the posterior edge of the scapula, at the bottom of the supraglenoid fossa. In the lizard, and no doubt in the other forms, the foramen lies just laterad of the area of insertion of the long head of the triceps muscle. In the lizard, however, there is no fossa. The canal passes from the foramen upward and forward, to open finally upon the inner surface of the scapula. In *Crotaphytus* and *Varanus* this canal is of considerable length, the inner opening being well above the middle of the scapula.

In most Theromorpha, and in *Diplocaulus*, on the other hand, there is no canal, and the foramen is not on the posterior margin, but farther forward, on the flat surface of the scapula.

It would seem that the form and position occurring in the lizards is the primitive one, since it is the type of both the Temnospondyli and the Cotylosauria. Apparently, the lizard is the only mesozoic or modern tetrapod which has retained this structure. Gunther shows a foramen piercing the scapula of *Sphenodon* (article not available to the author), but two scapulæ at hand show no evidence of it.

In determining the function of this foramen the writer has dissected four specimens of *Crotaphytus collaris*. It was seen at once that the foramen was used for the passage of a blood vessel, and was not used by the nervous system. In order to determine the exact relation and identity of this vessel, the

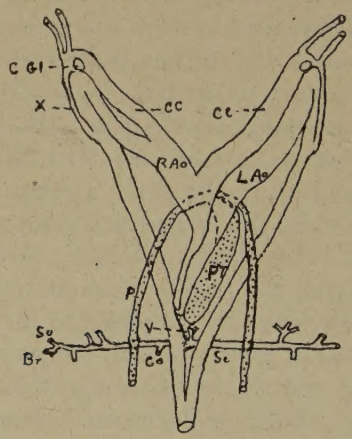

FIG. 1. Aortic arches and subclavian of *Crotaphytus collaris*. *Br*, brachiel artery; *CC*, common carotid artery; *C GI*, carotid gland; *LAo*, left aorta; *P*, pulmonary artery; *PT*, Pulmonary trunk; *RAo*, right aorta; *Sc*, subclavian artery; *Su*, subscapularis artery; *V*, vertebral trunk; *X*, Carotid-systemic connection..

subclavian and axillary arteries were traced out in detail. This very interesting system in the lizard has been traced out in detail for *Psammosaurus griseus* by Corti (1853). The writer does not have access to his account. Hoffmann's account in Bronn's Thierreichs is based upon Corti, but is necessarily condensed. It is not possible, therefore, to compare *Crotaphytus* with his account. Hoffmann makes no mention of the supraglenoid canal, from which it seems that it was not observed by Corti. Possibly the canal is not present in *Psammosaurus*.

In *Crotaphytus* (Fig. 1) the two subclavians come off from near the lower end of the right aorta by a single stem. After about 1 mm. this common stem divides, and the two subclaviæ pass directly laterad to the arm. At the point of their separation, in the median line of the body, the vertebral artery is given off as a single vessel. It runs directly forward on the ventral surface of the centrum for about 2 mm. and then divides into right and left vertebral arteries.

The costocervical axis leaves the subclavian just laterad of the centrum, and sinks at once into the muscles of the back.

Beyond the costocervical, the subclavian passes beneath the heavy *longus colli* muscle. Beneath the outer portion of this muscle it gives off two or three small branches which pass to the adjacent anterior regions. These should represent the thyrocervical axis. A little further laterad another vessel leaving the subclavian on the posterior side is no doubt the internal mammary artery.

The axillary artery divides almost immediately. The brachial continues down the arm in the usual manner. The lateral branch, which is without doubt the subscapularis, passes towards the space between the *latissimus dorsi* and a muscle which corresponds in position and relations to the *teres*. The subscapularis divides almost at once. The most posterior branch divides soon into three branches, which spread over the surface of the last-named muscle. The other branch turns towards the axis of the limb, over the proximal portion of the long head of the triceps, and into the space between this muscle and the humerus. Here it divides into several branches, one of which passes through the canal in question, to supply the subscapularis muscle.

There can be no reasonable doubt but that the supraglenoid foramen and canal in all forms in which it occurs, has the same function as the lizard; that is, that it serves as a passage for a branch of the subscapularis muscle. In mammals the subscapularis artery proper passes laterad of the scapula and its muscles, while only a minor branch passes to the subscapularis muscle. In the lizard, however, this branch seems to be the most important one.

BIBLIOGRAPHY.

CORTI. De Systemate Varsorum *Psammosauri grisei.* 1853.

GUENTHER. Contribution to the Anatomy of Hatteria. Philos. Trans. Roy. Soc. Lond. 1867.

HOFFMANN, C. K., in Bronn's Thierreichs, vol. 6, part 3, division 2. Eideschsen und Wasserechsen.

RATHKE. Untersuchungen ueber die Aortenwurzeln der Saurier. Denkschr. Wien. Akad. 1857.

WILLISTON, S. W. A New Family of Reptiles from the Permian of New Mexico. Amer. Journ. Sci., vol. 31, pp. 389-391.

□